

Cardiorespiratory Scars

Axillary thoracotomy

- Muscle sparing approach
- OPERATIONS: **pneumothorax**, pleurectomy, pulmonary resections (pneumonectomy/lobectomy/ wedge)

Posterolateral thoracotomy

- Most common
- Patient placed in lateral decubitus position
- OPERATIONS: **pulmonary resections** (pneumonectomy/lobectomy/ wedge), oesophageal surgery, chest wall resection
- DETAIL: cut through intercostal space beginning inferomedially to tip of scapula

Median sternotomy

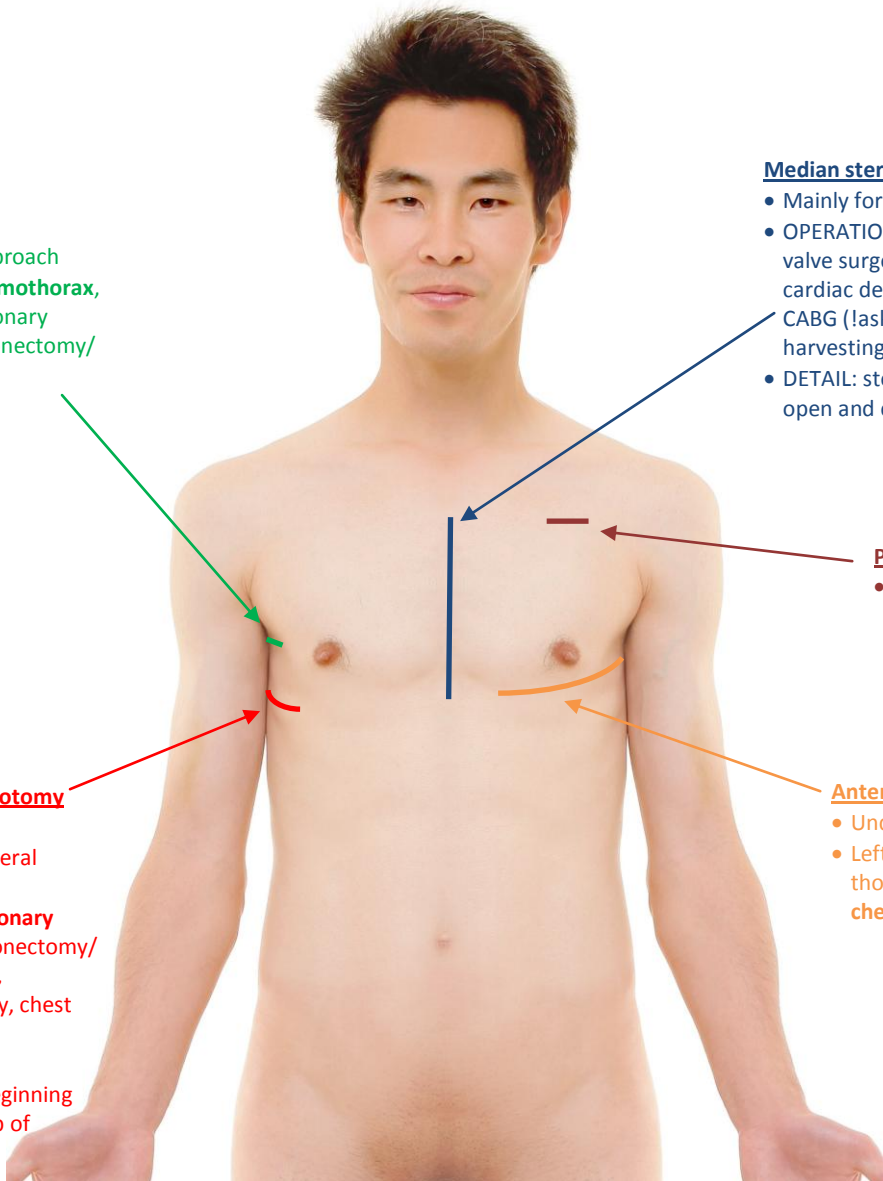
- Mainly for **open heart surgery**
- OPERATIONS: transplant, valve surgery, congenital cardiac defect corrections, CABG (ask to look for vein harvesting scar on legs)
- DETAIL: sternum is cracked open and chest opened

Pacemaker scar

- OPERATIONS: pacemaker insertion

Anterolateral thoracotomy

- Under breast
- Left anterolateral thoracotomy is used for **open chest massage**



Abdominal Scars

